



# Brand specific responses to smokeless tobacco in a rat lip canal model

Joel L. Schwartz<sup>1,2</sup>, Klaus D. Brunnemann<sup>3</sup>, Alexander J. Adami<sup>1</sup>, Suchismita Panda<sup>1</sup>, Sara C. Gordon<sup>1</sup>, Dietrich Hoffmann<sup>2</sup>, Guy R. Adami<sup>1,4</sup>

<sup>1</sup>Department of Oral Medicine and Diagnostics, University of Illinois at Chicago, Chicago, IL, USA; <sup>2</sup>American Health Foundation Cancer Center, Institute for Cancer Prevention, Valhalla, NY, USA [no longer operating]; <sup>3</sup>Department of Pathology, New York Medical College, Valhalla, NY, USA; <sup>4</sup>Center for Molecular Biology of Oral Diseases, University of Illinois at Chicago, Chicago, IL, USA

**BACKGROUND:** Different compositions of smokeless tobacco (ST) are widely thought to cause oral carcinoma at different rates but there is little direct evidence for this hypothesis.

**METHODS:** We used a rat lip canal model to examine the mucosal changes induced by chronic daily exposure to four different brands of ST: Skoal, Copenhagen, Ettan Swedish Snus, and Stonewall, differing in measured levels of: tobacco specific nitrosamines (TSNAs), unprotonated nicotine, moisture, and pH.

**RESULTS:** Exposure to the lip canal for 12 months produced changes in the mucosa marked by increases in S phase and M phase cells for the Skoal and Copenhagen exposed rats. This correlated with the high level of TSNAs and nicotine in these products. All the tobacco products, to different degrees, induced sites of moderate to severe dysplasia some with extensive rete peg outgrowth from the oral mucosa not seen in the controls. Many of these sites showed a loss of p16 expression.

**CONCLUSIONS:** While all ST products caused dysplasia, the products with lower levels of TSNAs and unprotonated nicotine caused less, consistent with the model that tobacco with low levels of nitrosamines might potentially induce fewer carcinomas in human users.

*J Oral Pathol Med* (2010) **39**: 453–459

**Keywords:** dysplasia; lip canal; nitrosamines; smokeless tobacco; squamous cell carcinoma

## Introduction

Smokeless tobacco (ST) can cause experimental and clinical oral squamous cell carcinoma (OSCC) (Surgeon

General Report 2003) and is associated with snuff dippers keratosis, gingivitis, periodontitis, gingival recession, epithelial attachment, and caries (1). A recent Federal Trade Commission report stated the number of pounds of ST sold in the United States as of 2005 had increased by 3% since 2002. In part as a result of increases in the number of municipal bans on tobacco smoke, and increased taxing of tobacco smoke products, a shift to ST products is occurring.

Usage of ST in the form of loose tobacco or snuff correlates with increased rates of oral carcinogenesis in humans, although at lower rates than that caused by smoking tobacco (2–5). Animal models have been used to explore a causative role. Rats surgicized to create a lip canal lined by oral mucosa, where ST is placed twice daily showed increased rates of malignant oral tumors (3, 6). The surgery and subsequent inflammation, along with mechanical injury resulting from tobacco placement, may have contributed to the tumor induction, although controls with cotton instead of ST exposure showed no dysplasia or tumors (6, 7). Additional studies, with the application of purified nitrosamines 4-(methylnitrosamino)-1-(3-pyridyl)-1-butanone (NNK) and NO nitrosonornicotine (NNN), the predominant carcinogenic tobacco specific nitrosamines (TSNAs) in ST, have identified these chemicals as genotoxins and as oral carcinogens (8). These TSNAs, in combination with nicotine, hydrogen peroxide or additional agents induced oral tumors in non-surgicized rat mucosa and in the hamster cheek pouch, and with snuff in the rat lip canal (9, 10). This is suggestive of a causative role of TSNAs and ST in the oral carcinogenesis in humans.

Relative short term usage of snuff ST by humans induces characteristic non-neoplastic mucosal change known as snuff dippers' lesion. This is frequently a white corrugated lesion of the oral mucosa typically at the site of ST placement which can remain for years with continued usage. Microscopically, increased keratin (hyperkeratosis) and epithelial thickening (which can be hyperplasia) are seen which is rarely accompanied by

Correspondence: Joel L. Schwartz, Department of Oral Medicine and Diagnostics, University of Illinois at Chicago, 801 S. Paulina St. M/C 838. Chicago, IL 60612-7213, USA. Tel: +1 312 355 4311, Fax: +1 312 355 2688, E-mail: joschwar@uic.edu  
Accepted for publication February 7, 2010

mild dysplasia all of which are reversible (11). Pre-malignant changes – moderate and severe dysplasia – are irreversible changes with an increased probability of progression to oral cancer (10, 12). Additional molecular changes associated with malignancy are very high proliferative indexes and decreases in p16 immunoreactivity in human papilloma virus (HPV) unrelated malignancies (13–16). The irreversible changes take years to occur in humans.

It is widely assumed, with scant evidence, that TSNA levels in ST are a major causative factor for oral cancer (1, 4, 17). However, there are approximately 30 different carcinogens in ST in addition to NNK and NNN which are present at different levels in the various products (18). Other ST components such as moisture which can influence stickiness, pH which can affect mucosal absorption of components such as nicotine, and the nicotine content itself, which induces rapid histologic changes, also can vary and may have effects on carcinogenicity (18–20). Higher relative risk for oral cancer for ST users vs. non-users in the United States, 2.6, compared with Sweden and Norway 1.0 (1) based on five separate studies of United States and four of Norwegian or Swedish male users in the past, coincided with the higher general TSNA levels in U.S. ST (5, 21–29), although other explanations for this difference are possible (1). One group has compared three different snuffs over a 3 month period of usage, and found significantly fewer effects on the oral mucosa with some brands (2, 30). Differences in short term histologic changes induced by loose vs. packaged snuff have been noted and attributed to differences in levels of absorbable nicotine (20, 31). With a paucity of randomized controlled studies, there is very little direct evidence for, or against, different snuffs having different rates of carcinogenesis.

This study was undertaken to assess long term changes induced by daily usage of four different ST formulas studied side by side and applied under identical protocols in an animal model. These snuffs, Skoal, Copenhagen, Ettan Swedish Snus and Stonewall, differ by many fold in TSNA concentrations, and also have different pH and nicotine and moisture content. Use of the rat model allows twice daily application of ST in a model which has shown a progression of disease, first snuff dippers oral keratosis (mild dysplasia) next moderate to severe dysplasia, and last invasive cancer in <2 years. This animal model will allow us to test if usage of each ST product has different morbidity with a focus on early histopathology prior to stromal invasion.

## Materials and methods

### *Animals and surgery for lip canal*

Sprague Dawley rats 4–6 weeks of age were surgicized as described to produce a lip canal which is an everted lip formed into a tube (8, 32). Snuff is placed in the mucosal lined tube two times a day, five days a week for 12 months in 15 rats per group starting 3 weeks after surgery, in only well constructed, canals in healthy rats with no weight loss. Healing and lack of inflammation were verified by histologic examination of lip canal

tissue from five rats that were terminated 3 weeks after surgery (data not shown).

### *Snuffs*

Into the lip canal was placed as a control, cotton, or 150–200 mg of four different ST products using a sterile straw and a sterile stainless steel plunger. Stonewall was provided to us from Star Scientific Inc. (Petersburg, VA, USA), all other STs were purchased as sleeves of ten packs, locally in 15 stores in New York City, in the counties of Westchester, Putnam, and Rockland (NY) and Fairfield county (CT) or shipped from Sweden via overnight mail. After all required purchases were done (150 cans of each ST) the contents of each can of each brand was thoroughly mixed and then stored at 6°C in large glass containers that were securely closed to minimize oxidation (33).

### *Tobacco specific nitrosamine*

Tobacco specific nitrosamine levels of the STs under investigation were obtained as previously described and were from duplicates of samples from a one time assessment as were other composition measurements (34).

### *Histopathology and assessment of degree of dysplasia*

To establish the relative degree of mucosal changes associated with ST exposure, hematoxylin and eosin stained lip canal tissue sections from the five groups were blindly graded by a single oral pathologist with confirmatory review of a subset from each group by a second. Ten to twelve animals with relatively large amounts of lip canal visible (at least 40–60 µm) in thin section were studied per group. Areas of possible abnormal tissue structure were located at 25× light microscopy magnification and then reviewed at 400× to determine the number of nuclear abnormalities associated with OSCC. Pathology grading of the tissue sections was based on these dysplastic characteristics: pleomorphism, designated as a variability in nuclear size of  $\pm 2$  µm (smaller or larger than normal oral keratinocytes observed in normal oral mucosa); hyperchromatism defined as an increase in nuclear staining; and bizarre mitoses exhibiting a duplex, triplex or greater irregular arrangement of chromatin along a metaphase spindle. Grade + abnormal mucosa architecture without dysplasia (can be because of oblique tissue sections), variable hyperkeratosis and hyperplasia; Grade ++ mild dysplasia characterized by low levels of pleomorphism and hyperchromatism at the stratum basalis and adjacent layers, with hyperkeratosis and hyperplasia also typically observed; Grade +++ moderate to severe dysplasia with high levels of pleomorphism and hyperchromatism with abnormal mitoses in lower 1/3 to 2/3 of epithelium at sites of rete pegs extending into the stroma.

### *Immunohistochemistry of tissue sections*

Deparaffinization, antigen retrieval and staining with primary, secondary antibody, avidin–biotin binding, and peroxidase detection detection was conducted using an automated instrument (Ventana Medical Systems, Tucson, AZ, USA) or with the ABC Kit (Vector

Laboratories, Burlington, CA, USA). Cell proliferation was assessed using primary antibody to proliferating cell nuclear antigen (PCNA) (polyclonal rabbit, anti-human, Santa Cruz Biotechnology, Inc., Santa Cruz, CA, USA) without antigen retrieval and adjacent sections stained with hematoxylin for cell counts. PCNA counts were in regions of higher numbers of positive epithelial cells. For p16 quantitation primary antibody to p16 (monoclonal mouse, clone F-12, Santa Cruz Biotechnology, Inc.) (35) was used and hematoxylin counterstaining was carried out to visualize the stratum basalis which was the subject of the count. Areas of abnormal tissue architecture suggesting invasive growth or when available regions of pleomorphism, hyperchromatism and/or bizarre mitoses, were the first focus of the p16 count. When these were not present in sufficient numbers random fields were scored for a total of four 40× fields for each count.

#### Statistical evaluation

The Wilcoxon rank sum test was used to compare the differences in pathology for each ST exposure group. A one-way ANOVA was used to compare the significance in the difference in p16, PCNA and mitotic counts in the different exposure groups with the Bonferroni test run *post hoc*.

## Results

#### Snuff composition

Analyzes of each snuff's composition were performed to quantitate pH, moisture content, levels of unprotonated nicotine, and TSNA both at the beginning and end of the study. The pH for Ettan Snus, Skoal, Copenhagen, and Stonewall were 8.52, 8.00, 7.86, and 7.70, respectively. Moisture content was nearly identical in Skoal, Copenhagen, and Ettan Snus at approximately 53% but was substantially lower in Stonewall at 12%. Levels of unprotonated nicotine were identical in Skoal and Copenhagen at 3.0%, in Ettan Snus, 1.9%, and Stonewall 1.4%. As expected the snuff compositions showed a wide range of TSNA concentrations (varying by over 60-fold). The brands from high to low were (Skoal, Copenhagen, Ettan Snus, and Stonewall) paralleling nicotine levels (Table 1).

#### Histopathologic changes induced with snuff exposure

Gross examination after 12 months of continual exposure to the various ST compositions demonstrated no large, visible tumors. However, microscopic evaluation of hematoxylin and eosin stained tissue sections revealed

changes in histopathology at significantly higher rates in all ST exposed rats vs. the controls (Fig. 1, Table 2). Sections from each group were given a pathological grade based chiefly on the dysplasia index and to a lesser degree the presence or lack of apparent changes at the epithelial/stromal interface (Figure S1). Skoal had the highest level of changes, which were significantly higher than: Ettan Snus,  $P < 0.00194$  and Stonewall,  $P < 0.00574$  (Table 2). Overall the two snuffs with the highest level of TSNA and unprotonated nicotine, Skoal and Copenhagen, induced significantly higher levels of dysplastic changes than the low TSNA/unprotonated nicotine STs, Ettan Snus and Stonewall, which were in turn higher than the control group.

#### Loss of p16 expression with snuff exposure

To strengthen the histopathology assessments of advanced dysplasia we selected p16, a marker that is present in normal oral keratinocytes even with hyperplasia, but has been consistently shown in rodents to be suppressed in expression in moderate and severely dysplastic and fully malignant oral epithelium (Fig. 2) (16, 35, 36). Focusing on non-normal appearing regions of the canal mucosa, we examined p16 levels in areas of moderate to severe dysplasia and/or abnormal epithelial extensions. Cotton exposed rats lacked dysplasia; rare areas of possible abnormal epithelial extensions showed no loss of p16 expression (Fig. 2). In contrast, in the Skoal exposed rats, areas of dysplasia and abnormal epithelial architecture were more common, and overall showed a decrease in p16 expression in the epithelial cells abutting the stroma. P16 levels in these regions induced by exposure to Skoal and Copenhagen, with high levels of TSNA and unprotonated nicotine, were lower than that induced by Ettan Snus and Stonewall STs which had much less TSNA and unprotonated nicotine.

#### Changes in cell proliferation with snuff exposure

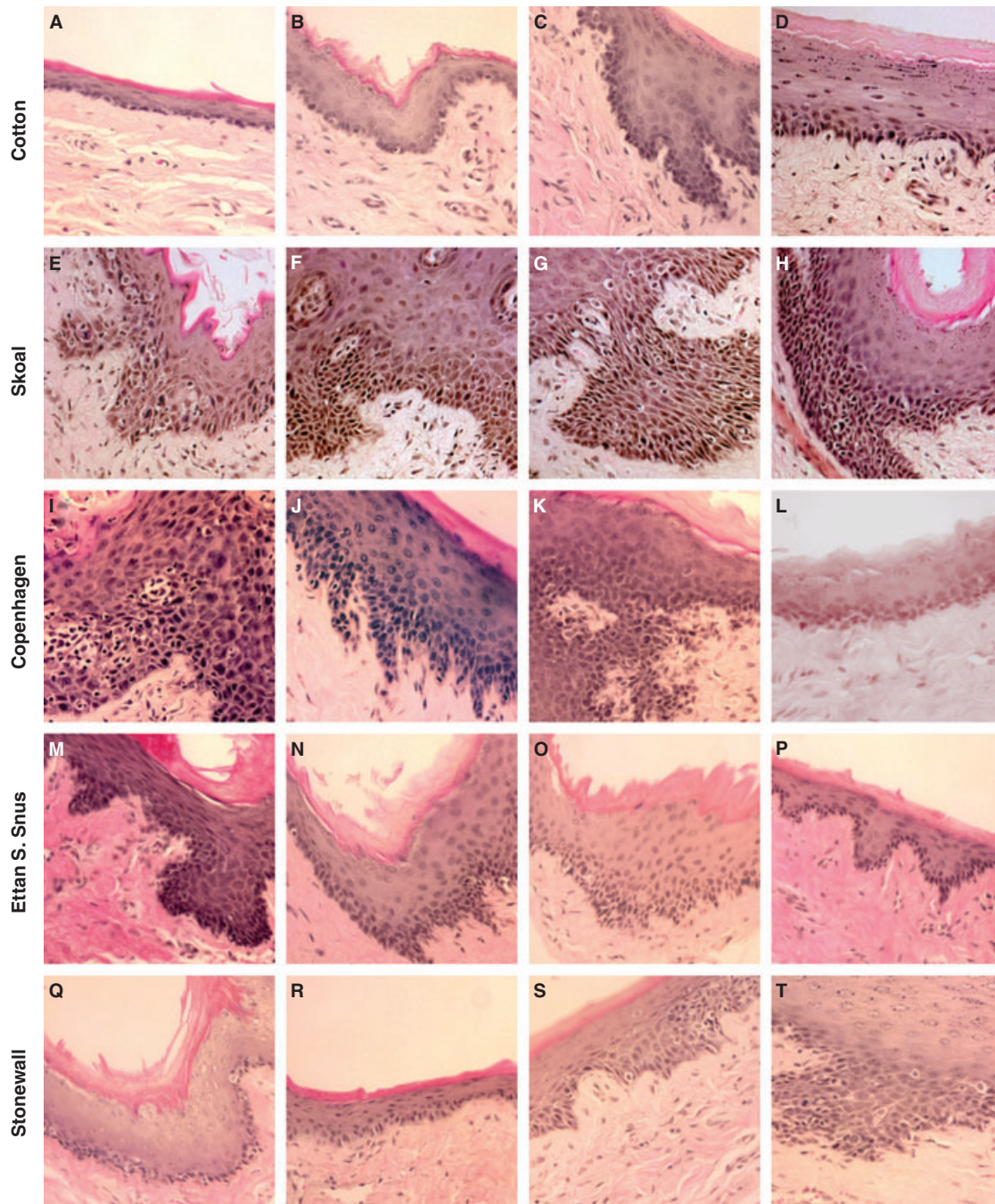
Nuclear PCNA is a marker of cell proliferation that can be associated with dysplasia and OSCC. Peak levels of PCNA positive cells, were found to be elevated in the rats exposed to the higher TSNA/unprotonated nicotine formulas from Skoal and Copenhagen vs. the control rats, and overall vs. rats exposed to the lower TSNA/nicotine products (Fig. 3). Little or no elevation of PCNA positive cells was seen respectively with the Ettan Snus or Stonewall exposed rats vs. the control. Quantitation of mitotic figures per unit length lip canal also saw an increase for rats exposed to high TSNA/unprotonated nicotine STs, Skoal and Copenhagen,

**Table 1** Quantity of TSNA in each ST used in this study

Brand	NNN (ppm)	NNK (ppm)	NAT (ppm)	NAB (ppm)	Total (TSNA) (ppm)
Skoal fine cut	20.8	4.3	36.8	2.1	64.0
Copenhagen	15.4	2.5	18.5	1.2	37.6
Ettan Snus	1.12	2.8	1.05	0.09	5.1
Stonewall	0.06	0.04	0.17	0.007	0.28

ST, smokeless tobacco; NNN, NO nitrososornicotine; NNK, nitrosamines 4-(methylnitrosamino)-1-(3-pyridyl)-1-butanone; NAT, N'-nitrosoanatabine; NAB, N'-nitrosoanabazine; TSNA, tobacco specific nitrosamines; ppm, part per million.





**Figure 1** Histopathologic findings for representative lip canal samples from each smokeless tobacco (ST) exposed group and control. Cotton: (A) oral mucosa with 5–6 layers of epithelium. Non-dysplastic. (B) Slight hyperplasia, hyperkeratosis. Non-dysplastic. (C) Extensive hyperplasia and hyperkeratosis. Non-dysplastic. (D) Extensive hyperkeratosis and hyperplasia. Non-dysplastic. Skoal: (E) hyperplasia, acanthosis, with hyperchromatism and pleomorphism extending past bottom 1/3 of epithelium with mitotic figures and one bizarre mitosis. Tear drop extension of growth into adjacent stroma featuring pleomorphism and hyperchromatism. Moderate to severe dysplasia. (F) Similar to (E) but with general downward growth of hyperchromatic and pleomorphic cells. Moderate to severe dysplasia. (G) Similar to (H) but with apparently well developed area of extension into stroma. Moderate to severe dysplasia. (H) Similar to (G). Moderate to severe dysplasia. Copenhagen: (I) extensive pleomorphism, hyperchromatism throughout the epithelium. Bizarre mitoses, dyskeratosis. Apparent extension of epithelium into stromal tissue. Severe dysplasia. (J) Hyperplasia, hyperkeratosis. Extended rete pegs with hyperchromatism and limited number of dyskeratotic cells. Moderate dysplasia. (K) Similar to (I) with growth pattern suggestive of stromal invasion. Severe dysplasia. (L) Hyperplasia, mild hyperkeratosis slight hyperchromatism. Mild dysplasia. Ettan S. Snus: (M) hyperplasia, hyperkeratosis. Basal cells exhibit hyperchromatism, dyskeratosis, and slight pleomorphism with one mitotic figure. Limited extension of growth into stroma. Mild dysplasia (N) similar to (M). Mild dysplasia. (O) Similar to (M) but with more extensive pleomorphism. Moderate dysplasia. (P) Localized hyperplasia and minor hyperchromatism. Non-dysplastic. Stonewall: (Q) hyperplasia and hyperkeratosis with some basal hyperchromatism. Compare to (D). Mild dysplasia. (R) Hyperplasia, slight hyperkeratosis with minor hyperchromatism. Mild dysplasia. (S) Hyperkeratosis and localized areas of hyperplasia with a few hyperchromatic and mitotic figures in cells. Mild dysplasia. (T) Extending from mucosa is an outgrowth into stroma of hyperchromatic and pleomorphic cells with slight anaplasia and some mitotic figures. Moderate dysplasia. Hematoxylin and eosin stained. Original magnification 200 $\times$ .

**Table 2** Distribution of samples among the different grades of histopathologic change

Group	Grade of histopathologic change		
	+	++	+++
Cotton control	9	1	0
Skoal	0	3	8
Copenhagen	2	5	4
Ettan Snus	2	9	1
Stonewall	3	7	2

Wicoxon Rank Sum test of significance of differences in the distributions reveals Skoal vs. control,  $P < 0.00112$ ; Copenhagen vs. control,  $P < 0.00151$ ; Ettan Snus vs. control,  $P < 0.00104$ ; Stonewall vs. control,  $P < .00340$ . Skoal vs. Copenhagen,  $P < 0.0704$ ; Skoal vs. Ettan Snus,  $P < 0.00194$ ; Skoal vs. Stonewall,  $P < 0.00574$ .

when considered together vs. the control group. Rats exposed to the lower level TSNA/unprotonated nicotine ST were not significantly different than the controls.

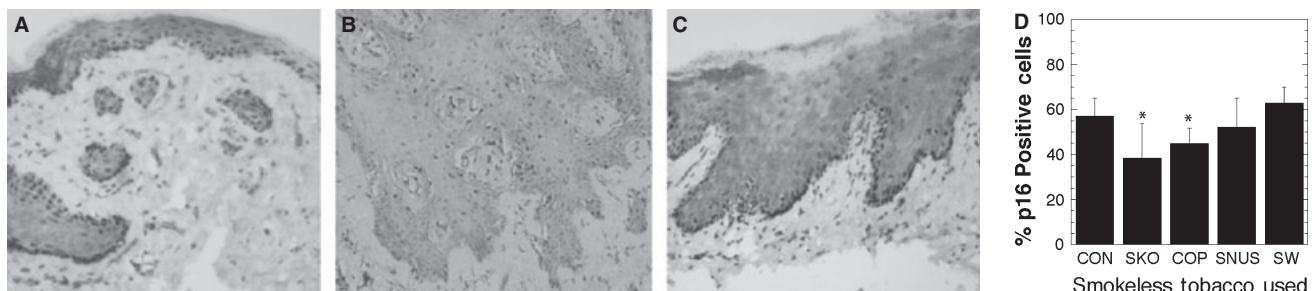
## Discussion

This study demonstrated that different ST products over a 12 month two times per day exposure caused moderate to severe dysplasia coincident with elaborate rete peg extension into the stroma, features ascribed to pre-malignancy when found in oral mucosa. While hyperchromatism and pleomorphism were at times at high levels they were typically restricted to the lower 1/3 or 2/3 of the epithelium. Moderate to severe dysplasia is thought to represent irreversible change, and when present in human patients require ablative therapy. Untreated moderate and severe dysplasia can go on to OSCC more frequently than other lesions do in humans, and probably in rodents, but these studies are hard to do making the true risk unknown (12). The data available suggest moderate to severe dysplasia without treatment presages OSCC approximately 50% of the time, although the frequency could be much lower making a diagnosis of pre-malignant tentative (12, 37). In an experiment to determine the irreversibility of these types of changes in the rat model, we saw moderate to severe dysplastic changes induced by exposure to Copenhagen ST remained 3 months after ending exposure (Joel L. Schwartz, personal communication). While a few lesions

resembling microinvasion were seen, the detection of early invasion into and across the lamina propria can be subject to errors (12, 27) as a result of mucosal abnormalities such as, for example, acanthotic rete peg extension into stroma in conjunction with areas of hyperkeratosis and hyperplasia. Also, tissue sectioning of the lip canal, a hollow tube formed from surgery, can produce oblique angled cuts making unequivocal diagnosis of early dermal invasion even more difficult. For that reason we refrained from identifying any of these lesions as micro-OSCCs and note that the identification as pre-malignancies is qualified.

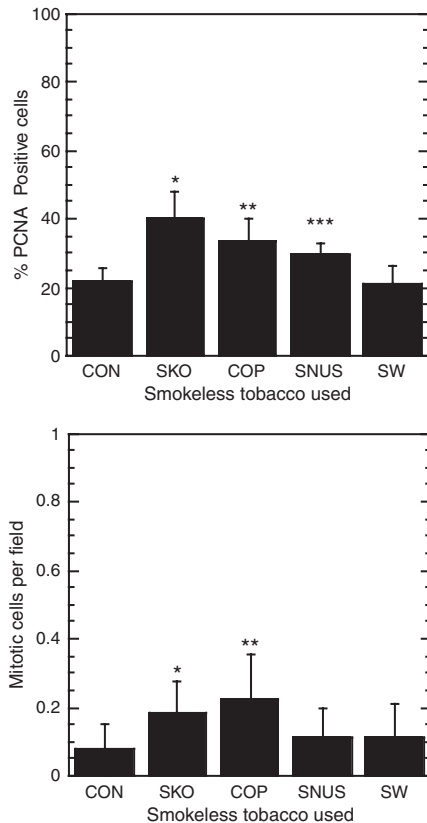
Proliferation markers, PCNA (Fig. 3), Ki-67 (data not shown) and mitotic figures (Fig. 3) showed an increase in Skoal and Copenhagen exposed rats as expected with tumor formation, although these are not tumor specific markers – unlike p16. During tumor formation and progression, the numbers of nuclei of the mucosal stratum basale positive for p16 tumor suppressor protein decreased, beginning with moderate to severe dysplasia, until almost totally absent at times in advanced carcinomas (15, 16, 35, 36). Importantly, a decrease in p16 level is not associated with reversible mucosal hyperkeratosis or hyperplasia (15, 16) changes that occur with short term exposure to snuff. In human OSCC there is some disagreement on when during tumor progression p16 expression is suppressed (15, 38). This may be because of variance in HPV involvement, and variability in tissue acquisition and fixation when archival tissues are used, or species specific differences. In the rats, we noted regions of ST exposed mucosa that appeared to exhibit high levels of epithelial extension into the stroma exhibited decreased levels of p16 positive cells in the basal layer compared with the cotton exposed control mucosa. This is similar to what is seen with rat OSCC induced by purified carcinogen. We found that focusing on regions of apparent abnormal epithelium and/or dysplasia, the numbers of p16 positive cells was decreased in the Skoal and Copenhagen rats vs. the control or compared together vs. Ettan Snus and Stonewall exposed rats, suggesting these regions show changes characteristic of malignancy (Fig. 2).

The rat lip canal system allows uniform usage, twice a day exposure and production of early mucosal lesions that histologically resemble those seen in human ST users. While more recent studies have shown the



**Figure 2** Immunohistochemical staining for p16 protein in suspect areas of rat, lip canal, oral mucosa. (A) Cotton exposed oral mucosa shows high numbers of p16 positive cells in the stratum basale. (B) Skoal exposed oral mucosa shows low levels of p16 positive cells in the stratum basale (C) Stonewall exposed oral mucosa shows high levels of p16 positive cells in the stratum basale with focal areas of higher intensity. Images are from formalin-fixed paraffin-embedded tissue sections at 200 $\times$ . (D) Shown is the mean percentage of p16 positive cells in the stratum basale of the ST and cotton exposed oral mucosa plus the standard deviation. \* $P < 0.002$  control vs. experimental groups.





**Figure 3** Examination of proliferation indices in smokeless tobacco (ST) exposed rat lip canal oral mucosa. (a) Labeling index for immunohistochemical staining for nuclear PCNA ST exposed and the cotton exposed oral mucosa. Shown is mean and standard deviation. \* $P < 0.0001$ , \*\* $P < 0.0009$ , \*\*\* $P < 0.0248$  control vs. experimental groups. (b) Counts of mitotic figures per 10  $\mu$ m length oral mucosa in hematoxylin and eosin stained tissue. Shown is the mean plus the standard deviation. \* $P < 0.0238$ ; \*\* $P < 0.00111$  control vs. experimental groups.

induction of carcinoma and sarcoma with long term rat lip canal ST exposure, the original study from thirty years ago did not (3, 6, 8, 32). Differences in the rats, ST product and its storage could be responsible. While the effects we saw were not reversible over a 3 month break from ST exposure (Joel L. Schwartz, personal communication), the next line of inquiry will be to show that the STs that induced moderately and severely dysplastic epithelial cells will with more time induce tumor masses with frank invasion of the stroma.

It is clear from many studies that the risk of oral malignant transformation is multifactorial (1). Genetic polymorphisms, for example in the alcohol dehydrogenase gene, exposure to environmental carcinogens, such as tobacco and alcohol and infection by virus (HPV 16/18) or even microorganisms can increase risk. Some of these interactions can induce inflammation which can contribute to the neoplastic process. In our study, all ST products produced varying degrees of acute, sub-acute and chronic inflammation in the stroma. In rare instances this inflammatory infiltrate occupied the epithelium extending from the stratum basalis to the stratum corneum. While we saw no correlation between the inflammation and dysplastic changes observed at the

one year endpoint it is reasonable to assume that ST induced inflammation earlier may contribute to the original development of the dysplasia and abnormal epithelial extensions.

The results presented in this study are consistent with the idea that continuous exposure to some ST products such as Skoal or Copenhagen are expected to contribute to an enhanced risk for OSCC, while others such as Ettan Snus or Stonewall would have lower levels of risk. The risk correlated with both nicotine and TSNA levels – which co-varied in the four brands we tested. The four formulations tested may also vary in many other constituents which may be responsible for some or all of the differences we saw and/or the residual risk for carcinogenicity among the lowest TSNA brands. We can definitely state that the Skoal and Copenhagen brands, the two higher TSNA/ unprotonated nicotine products, produced more histopathologic changes of the epithelium consistent with pre-malignancy. This would concur with the premise that reducing TSNA lessens oral carcinogenicity and supports the speculation that these two low TSNA tobacco products would be safer for human use in regard to tumor formation. More work needs to be carried out to identify TSNA level as the true cause of differential oral cancer susceptibility and further examine the usefulness of this rat model to predict snuff induced human oral cancers.

## Supporting Information

Additional Supporting Information may be found in the online version of this article:

**Figure S1** Representative micrographs of hematoxylin and eosin stained sections from four rats from each group of snuff exposed animals. These reveal typical changes in mucosal histology that occur with 12 months of ST exposure as described in the Materials and methods section. Original magnification was at 200 $\times$ .

Please note: Wiley-Blackwell are not responsible for the content or functionality of any supporting materials supplied by the authors. Any queries (other than missing material) should be directed to the corresponding author for the article.

## References

- Boffetta P, Hecht S, Gray N, Gupta P, Straif K. Smokeless tobacco and cancer. *Lancet Oncol* 2008; **9**: 667–75.
- Warnakulasuriya KA, Ralhan R. Clinical, pathological, cellular and molecular lesions caused by oral smokeless tobacco – a review. *J Oral Pathol Med* 2007; **36**: 63–77.
- Cogliano V, Straif K, Baan R, Grosse Y, Secretan B, El Ghissassi F. Smokeless tobacco and tobacco-related nitrosamines. *Lancet Oncol* 2004; **5**: 708.
- Levy DT, Mumford EA, Cummings KM, et al. The relative risks of a low-nitrosamine smokeless tobacco product compared with smoking cigarettes: estimates of a panel of experts. *Cancer Epidemiol Biomarkers Prev* 2004; **13**: 2035–42.
- Roosaar A, Johansson AL, Sandborgh-Englund G, Axell T, Nyren O. Cancer and mortality among users and nonusers of snus. *Int J Cancer* 2008; **123**: 168–73.

6. Johansson SL, Saidi J, Osterdahl BG, Smith RA. Promoting effect of snuff in rats initiated by 4-nitroquinoline-N-oxide or 7,12-dimethylbenz(a)anthracene. *Cancer Res* 1991; **51**: 4388–94.
7. Grasso P, Mann AH. Smokeless tobacco and oral cancer: an assessment of evidence derived from laboratory animals. *Food Chem Toxicol* 1998; **36**: 1015–29.
8. Hecht SS, Rivenson A, Braley J, DiBello J, Adams JD, Hoffmann D. Induction of oral cavity tumors in F344 rats by tobacco-specific nitrosamines and snuff. *Cancer Res* 1986; **46**: 4162–6.
9. Padma PR, Lalitha VS, Amonkar AJ, Bhide SV. Carcinogenicity studies on the two tobacco-specific N-nitrosamines, N'-nitrosonornicotine and 4-(methylnitrosamino)-1-(3-pyridyl)-1-butanone. *Carcinogenesis* 1989; **10**: 1997–2002.
10. Reibel J. Prognosis of oral pre-malignant lesions: significance of clinical, histopathological, and molecular biological characteristics. *Crit Rev Oral Biol Med* 2003; **14**: 47–62.
11. Larsson A, Axell T, Andersson G. Reversibility of snuff dippers' lesion in Swedish moist snuff users: a clinical and histologic follow-up study. *J Oral Pathol Med* 1991; **20**: 258–64.
12. Warnakulasuriya S, Reibel J, Bouquot J, Dabelsteen E. Oral epithelial dysplasia classification systems: predictive value, utility, weaknesses and scope for improvement. *J Oral Pathol Med* 2008; **37**: 127–33.
13. Pande P, Mathur M, Shukla NK, Ralhan R. pRb and p16 protein alterations in human oral tumorigenesis. *Oral Oncol* 1998; **34**: 396–403.
14. Papadimitrakopoulou V, Izzo J, Lippman SM, et al. Frequent inactivation of p16INK4a in oral premalignant lesions. *Oncogene* 1997; **14**: 1799–803.
15. Bradley KT, Budnick SD, Logani S. Immunohistochemical detection of p16INK4a in dysplastic lesions of the oral cavity. *Mod Pathol* 2006; **19**: 1310–6.
16. Vairaktaris E, Yapijakis C, Psyrris A, et al. Loss of tumour suppressor p16 expression in initial stages of oral oncogenesis. *Anticancer Res* 2007; **27**: 979–84.
17. Winn DM. Epidemiology of cancer and other systemic effects associated with the use of smokeless tobacco. *Adv Dent Res* 1997; **11**: 313–21.
18. Hoffmann D, Djordjevic MV. Chemical composition and carcinogenicity of smokeless tobacco. *Adv Dent Res* 1997; **11**: 322–9.
19. Rodu B, Jansson C. Smokeless tobacco and oral cancer: a review of the risks and determinants. *Crit Rev Oral Biol Med* 2004; **15**: 252–63.
20. Andersson G. Snuff-induced changes associated with the use of loose and portion-bag-packed Swedish moist snuff. A clinical, histological and follow-up study. *Swed Dent J Suppl* 1991; **75**: 1–89.
21. Blot WJ, McLaughlin JK, Winn DM, et al. Smoking and drinking in relation to oral and pharyngeal cancer. *Cancer Res* 1988; **48**: 3282–7.
22. Boffetta P, Aagnes B, Weiderpass E, Andersen A. Smokeless tobacco use and risk of cancer of the pancreas and other organs. *Int J Cancer* 2005; **114**: 992–5.
23. Luo J, Ye W, Zendejdel K, et al. Oral use of Swedish moist snuff (snus) and risk for cancer of the mouth, lung, and pancreas in male construction workers: a retrospective cohort study. *Lancet* 2007; **369**: 2015–20.
24. Schildt EB, Eriksson M, Hardell L, Magnuson A. Oral snuff, smoking habits and alcohol consumption in relation to oral cancer in a Swedish case-control study. *Int J Cancer* 1998; **77**: 341–6.
25. Stockwell HG, Lyman GH. Impact of smoking and smokeless tobacco on the risk of cancer of the head and neck. *Head Neck Surg* 1986; **9**: 104–10.
26. Winn DM, Blot WJ, Shy CM, Pickle LW, Toledo A, Fraumeni JF Jr. Snuff dipping and oral cancer among women in the southern United States. *N Engl J Med* 1981; **304**: 745–9.
27. Kabat GC, Chang CJ, Wynder EL. The role of tobacco, alcohol use, and body mass index in oral and pharyngeal cancer. *Int J Epidemiol* 1994; **23**: 1137–44.
28. Lewin F, Norell SE, Johansson H, et al. Smoking tobacco, oral snuff, and alcohol in the etiology of squamous cell carcinoma of the head and neck: a population-based case-referent study in Sweden. *Cancer* 1998; **82**: 1367–75.
29. Foulds J, Ramstrom L, Burke M, Fagerstrom K. Effect of smokeless tobacco (snus) on smoking and public health in Sweden. *Tob Control* 2003; **12**: 349–59.
30. Andersson G, Warfvinge G. The influence of pH and nicotine concentration in oral moist snuff on mucosal changes and salivary pH in Swedish snuff users. *Swed Dent J* 2003; **27**: 67–75.
31. Andersson G, Bjornberg G, Curvall M. Oral mucosal changes and nicotine disposition in users of Swedish smokeless tobacco products: a comparative study. *J Oral Pathol Med* 1994; **23**: 161–7.
32. Hirsch JM, Thilander H. Snuff-induced lesions of the oral mucosa – an experimental model in the rat. *J Oral Pathol* 1981; **10**: 342–53.
33. Djordjevic MV, Fan J, Bush LP, Brunnemann KD, Hoffmann D. Effects of storage on levels of tobacco N-nitrosamine and N-nitrosamino acid in U.S. moist snuff. *J Agric Food Chem* 1993; **41**: 1790–4.
34. Brunnemann KD, Qi J, Hoffmann D. Chemical profile of two types of oral snuff tobacco. *Food Chem Toxicol* 2002; **40**: 1699–703.
35. Hong Y, Li C, Xia J, Rhodus NL, Cheng B. Xp16(CDKN2A) expression during rat tongue carcinogenesis induced by 4-Nitroquinoline-1-oxide. *Oral Oncol* 2009; **45**: 640–4.
36. Kanojia D, Vaidya MM. 4-Nitroquinoline-1-oxide induced experimental oral carcinogenesis. *Oral Oncol* 2006; **42**: 655–67.
37. Cowan CG, Gregg TA, Napier SS, McKenna SM, Kee F. Potentially malignant oral lesions in Northern Ireland: a 20-year population-based perspective of malignant transformation. *Oral Dis* 2001; **7**: 18–24.
38. Buajeeb W, Poomsawat S, Punyasingsh J, Sanguansin S. Expression of p16 in oral cancer and premalignant lesions. *J Oral Pathol Med* 2009; **38**: 104–8.

## Acknowledgements

This work was supported by a grant DE13222 from the NIDCR and grants from Star Scientific and the University of Illinois at Chicago, Edward C. Wach Dental Research Fund. We thank Dr. David Crowe for reviewing a subset of the pathological grading.

## Conflict of interest statement

The first part of this study, which included the exposure of the rats to the different smokeless tobacco (ST) products was funded in part by a grant from Star Scientific, a manufacturer of one of the STs tested and was carried out at the Institute for Cancer Prevention. Data analysis and most of the histopathology were funded by a separate grant from the University of Illinois at Chicago where the work was completed. The relationship with Star Scientific ended in 2005 when the Institute for Cancer Prevention ceased operations.